

Optimizing Detection Rate and Characterization of Subtle Paroxysmal Neonatal Abnormal Facial Movements with Multi-Camera Video-Electroencephalogram Recordings

Francesco Pisani¹ Elena Pavlidis¹ Luca Cattani² Gianluigi Ferrari² Riccardo Raheli² Carlotta Spagnoli¹

¹ Child Neuropsychiatry Unit, Department of Neuroscience, University of Parma, Parma, Italy

² Department of Information Engineering, University of Parma, Parma, Italy

Address for correspondence Carlotta Spagnoli, MD, Child Neuropsychiatry Unit, Department of Neuroscience, University of Parma, via Gramsci, 14-43126 Parma, Italy (e-mail: carlotta.spagnoli@gmail.com).

Neuropediatrics

Abstract

Objectives We retrospectively analyze the diagnostic accuracy for paroxysmal abnormal facial movements, comparing one camera versus multi-camera approach.

Background Polygraphic video-electroencephalogram (vEEG) recording is the current gold standard for brain monitoring in high-risk newborns, especially when neonatal seizures are suspected. One camera synchronized with the EEG is commonly used.

Methods Since mid-June 2012, we have started using multiple cameras, one of which point toward newborns' faces. We evaluated vEEGs recorded in newborns in the study period between mid-June 2012 and the end of September 2014 and compared, for each recording, the diagnostic accuracies obtained with one-camera and multi-camera approaches.

Results We recorded 147 vEEGs from 87 newborns and found 73 episodes of paroxysmal facial abnormal movements in 18 vEEGs of 11 newborns with the multi-camera approach. By using the single-camera approach, only 28.8% of these events were identified (21/73). Ten positive vEEGs with multicamera with 52 paroxysmal facial abnormal movements (52/73, 71.2%) would have been considered as negative with the single-camera approach.

Conclusions The use of one additional facial camera can significantly increase the diagnostic accuracy of vEEGs in the detection of paroxysmal abnormal facial movements in the newborns.

Keywords

- ▶ vEEG
- ▶ newborn
- ▶ subtle seizures
- ▶ paroxysmal nonepileptic events
- ▶ detection rate

Background

Polygraphic conventional video-electroencephalogram (vEEG) is established as the gold standard for brain monitoring in newborns, especially in the setting of suspected or confirmed neonatal seizures diagnosis.¹

What is generally referred to is a video recording with one single camera synchronized to EEG. Nevertheless, the use of more than one correctly oriented camera could be beneficial

in terms of enhanced recognition of minor motor phenomena, especially confined to the face, thus allowing the recognition of abnormal ocular movements and subtle seizures. The use of a dedicated camera for the patient's face, together with traditional cameras for the whole body, could allow more accurate description of clinical correlates to neonatal seizures and precise differential diagnosis between electrographic-only and subtle seizures. In some cases, in current clinical practice, only accurate offline review of video-recordings can

received
June 26, 2015
accepted after revision
February 22, 2016

© Georg Thieme Verlag KG
Stuttgart · New York

DOI <http://dx.doi.org/10.1055/s-0036-1582245>.
ISSN 0174-304X.

allow correct classification of such events. However, even in this case, subtle motor phenomena may be missed if not specifically looked for. Moreover, this approach could be used to accurately record ocular movements, thus reducing the risk of overlooking specific diagnoses.²

The aim of our study was to retrospectively review vEEGs to comparatively analyze the diagnostic accuracy in paroxysmal abnormal facial movement recognition, using the conventional single-camera approach, in a comparative way with respect to multi-camera approach.

Methods

Since mid-June 2012, we have started to monitor newborns with three orthogonal video-cameras (►Fig. 1). For the purposes of this article we retrospectively reviewed digital polygraphic vEEGs undertaken between June 16, 2012, and September 30, 2014. We first looked at the recordings using the multiple cameras approach, with specific coverage of the facial area, and we compared the diagnostic accuracy of this method with that of conventional vEEG recordings based on information coming from one single camera, thus ignoring the additional cameras' information. To decide on the presence or absence of abnormal movements, we did not rely on annotations by our neurophysiology technician, but only on reviewed video data.

Additionally, we also reviewed EEG requests and classified them into the following categories: hypoxic-ischemic injury, paroxysmal events/suspected neonatal seizures, preterm newborns follow-up/intraventricular hemorrhage, abnormal neurological status/examination, neonatal abstinence syndrome/intrauterine drug exposure, malformations/genetic syndromes/prenatal ultrasound diagnosis, other medical

conditions/ALTE (apparent life-threatening event) protocol, central nervous system infection.

The correct orientation of the cameras in the three spatial dimensions is crucial in providing the widest possible view of the neonate: the first camera takes a longitudinal view of the newborn, the second camera a transversal one, and the third camera aims the patient's face (►Fig. 1).

The technical features of the three color digital cameras can be summarized as follows: 59 × 55 × 121 mm dimensions and maximal resolution of 1,024 × 768 pixels, for the front camera; 50 × 55 × 110 mm dimensions and maximal resolution of 1,920 × 1,080 pixels, for the camera positioned laterally; 35 × 25 × 15 mm dimensions and maximal resolution of 560 × 420 pixels, for the microcamera pointing to the newborn's face. Cameras are linked to a mixer supporting up to four cameras, with a resolution of 720 × 576 pixels, a frame rate of 25 frames/second, dimensions equal to 210 × 149 × 43 mm and a weight of 1,100 g. Therefore, the synchronized video recordings in output from the mixer have a global resolution of 720 × 576 pixels, divided into four subframes (one for each supported camera) with a resolution of 360 × 288 pixels each. Synchronized video recordings show these characteristics: sampling rate of 25 frames/second and video resolution of 320 × 240 pixels.

Clinical indications for vEEG monitoring and technical details on how vEEG were recorded have been described in previous publications.^{3,4}

We documented both neonatal seizures (requiring electrographic confirmation for diagnosis) and nonepileptic paroxysmal motor phenomena,⁵ in which the paroxysmal motor event is not accompanied by EEG discharges fulfilling neonatal seizure diagnosis criteria.⁶

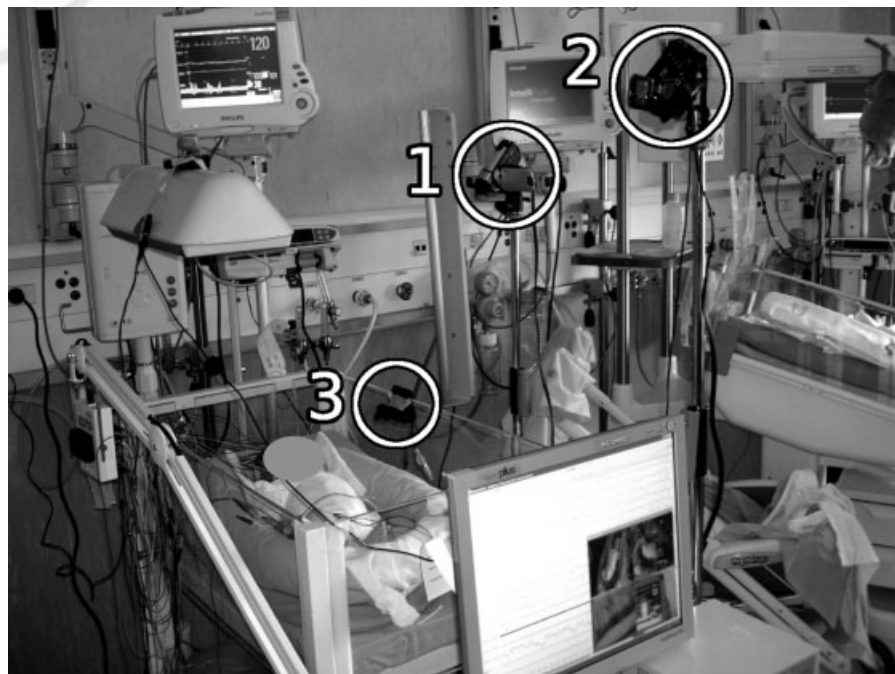


Fig. 1 Synchronized video acquisition system with multiple multiplanar cameras, based on the use of three cameras: the first one is positioned in front of the cradle, the second laterally to the cradle, and the third one is set at the edge of the cradle to frame the newborn's face.

We evaluated vEEGs recorded in the study period for the presence of neonatal seizures and of paroxysmal abnormal movements involving the face. We also noted paroxysmal abnormal movements not involving the face, and reported the different types and number of positive vEEGs.

For patients showing paroxysmal abnormal facial movements, we reported the type of movement, the number of detected episodes, the presence or absence of EEG discharges associated with the episodes, and the presence or absence of other neonatal seizures in the same vEEGs.

We calculated the number of episodes of paroxysmal abnormal facial movements detected with the two different methods (i.e., one camera vs. three cameras), and used their ratio as a measure of the change in diagnostic accuracy between the two methods.

Local ethics committee approval was obtained.

Results

During the study period between June 16, 2012 and September 30, 2014, 147 vEEGs from 87 newborns (average number of vEEGs/patient: 1.7, range: 1–6) were recorded using the three-camera approach. In the majority of cases (35 patients, 40.2%) vEEG was requested to investigate paroxysmal events and suspected neonatal seizures, while in 20 patients (22.3%) vEEG was requested as part of the evaluation and follow-up of preterm newborns. The third most common indication for vEEG was hypoxic–ischemic encephalopathy (16 patients, 18.4%). The complete list of causes for vEEG referrals is reported in ►Table 1.

From a total number of 147 vEEGs recorded in the study period, we discarded 80 negative vEEGs (absence of paroxysmal abnormal movements and of neonatal seizures). Eleven vEEGs contained neonatal seizures, but no paroxysmal abnormal facial movements (►Fig. 2). Finally, 38 vEEGs contained paroxysmal abnormal movements not involving the face (►Fig. 2). The whole range of recorded paroxysmal body movements is reported in ►Table 2.

With the multi-camera approach, we were able to identify paroxysmal abnormal ocular and/or facial movements in 18 vEEGs from 11 patients (►Fig. 2). These figures correspond to 12.2% (18/147) positive vEEGs and to 12.6% (11/87) newborns showing positive paroxysmal facial findings. Detailed information about our findings is reported in ►Table 3. Oromotor automatisms represented the most frequent isolated paroxysmal abnormal facial movement in our cohort, with 20 episodes from five patients (eight vEEGs), followed by isolated sucking automatisms (10 episodes from four vEEGs of two patients). However, automatisms were often found in association with other movements. The most frequent association was with tongue protrusion (15 episodes recorded in four vEEGs, from two patients). We also recorded 17 events involving the eyes (nystagmus, eye deviation, repetitive eye movements, eyelid clonic jerks) in four patients (five vEEGs), and these were more often associated than isolated. In five patients (five vEEGs), facial events were associated with extrafacial abnormal movements.

Table 1 Reason for first EEG request in the whole cohort of newborns, divided into two subgroups according to the period of use of one versus more than one camera

EEG requests	n (%)
Hypoxic–ischemic damage	16 (18.4)
Paroxysmal events/suspected neonatal seizures	35 (40.2)
Preterm newborns follow-up/IVH	20 (22.3)
Abnormal neurological status/examination	7 (8)
Neonatal abstinence syndrome/intrauterine drugs exposure	1 (1.1)
Malformations/genetic syndromes/prenatal ultrasound diagnosis	4 (4.6)
Other medical conditions/ALTE protocol	0
CNS infection	4 (4.6)
Total number of patients	87 (100)

Abbreviations: ALTE, apparent life-threatening event; CNS, central nervous system; EEG, electroencephalogram; IVH, intraventricular hemorrhage.

Note: Only the initial request for each patient is reported (requests for control EEGs are not taken into account).

The majority of our patients with positive facial findings also had neonatal seizures, but not always synchronous with the facial movements (8/11). Namely, three patients, although the facial paroxysmal movements were not related to clear EEG discharges, also had neonatal seizures in the same recordings not involving the face. Paroxysmal events involving the face were associated with EEG discharges and therefore represented neonatal seizures in five patients (five vEEGs). Three of these patients also had additional neonatal seizures and they fulfilled the criteria for neonatal status epilepticus due to the presence of recurrent seizures for more than 50% of the recording. From the neurophysiological point of view, ictal discharges were represented by: spikes and sharp waves in one case and by delta-alpha activity evolving into spikes-and-slow-waves in another case, delta/delta-theta or delta and theta-alpha discharges in three patients.

By comparing the number of episodes of abnormal facial movements detected with the multi-camera approach (73 episodes) with the ones visible with the single-camera approach (21 episodes), we found that the single-camera approach would have missed 71.2% of the total number of episodes detected with the multi-camera approach.

Additionally, 10 vEEGs would have been considered as negative for facial paroxysmal abnormal movements with the single-camera approach, as in only 8 vEEGs (from seven patients) this approach was able to detect subtle facial abnormal movements. However, 7 out of 11 patients had at least one positive vEEG with the single-camera approach (►Table 3).

Discussion

On the basis of our results, we conclude that the proposed multi-camera method can be useful in detecting subtle motor phenomena involving the face which might be otherwise overlooked or not fully appreciated.

Table 2 Number of vEEGs and of newborns without paroxysmal facial abnormal movements showing different paroxysmal nonepileptic abnormal movements in other body parts

	Number of vEEGs (number of newborns)
Nonepileptic myoclonic jerks	12 (9)
Excessive startles	1 (1)
Benign sleep myoclonus	5 (4)
Tremors	5 (4)
Tremors + myoclonic jerks	7 (6)
Tremors + non-epileptic clonic jerks	2 (2)
Dystonic posturing + tremors	2 (1)
Dystonic posturing + tremors + myoclonic jerks	1 (1)
Spontaneous + reflex nonepileptic clonic jerks + hypertonus	3 (1)

Abbreviation: vEEG, video-EEG.

In fact, the conventional use of one camera would have missed the detection of 71.2% of the facial paroxysmal events detected with our new method.

Although these data represent retrospectively acquired preliminary results for which we only provide a descriptive statistical analysis of relative frequencies, an improvement in our detection rate can be appreciated.

Therefore, our methodology might more easily enable neonatal neurologists or neurophysiologists to answer specific diagnostic questions, for example, to confirm that a typical clinical event (as noticed by parents or attending neonatologists) has been captured and does/does not have

an electrographic correlation.⁷ This might be particularly relevant in cases experiencing both neonatal seizures and nonepileptic motor phenomena, which constitute a relevant group in our cohort (3 newborns out of 11 with abnormal facial movements). Polygraphic synchronized vEEG recording with a single camera is already recommended as a way to reduce the risk of misinterpreting the epileptic or nonepileptic nature of a motor phenomenon, which would otherwise be unreliably established even by experienced professionals.⁸ In such cases, vEEG with multiple cameras can enable neonatal neurophysiologists/neurologists to give more detailed indications to attending neonatologists about

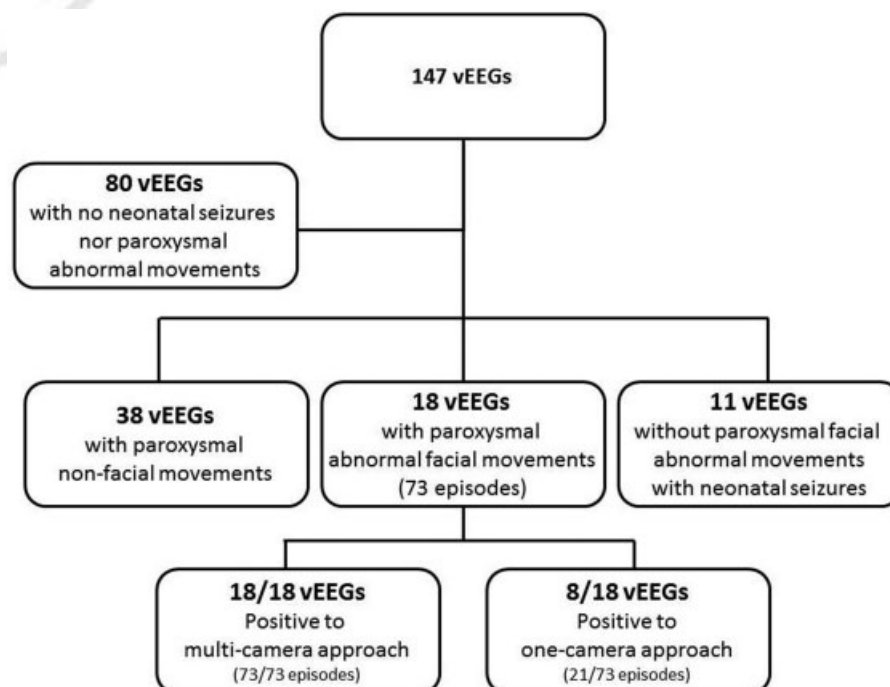
**Fig. 2** Results flowchart showing vEEG findings in our cohort of patients. NS, neonatal seizures; vEEG, video-EEG.

Table 3 Diagnostic accuracy using the multi-camera versus the single-camera approach for recognition of paroxysmal abnormal facial movements in newborns

	Pt 1 VEEG 1	Pt 1 VEEG 2	Pt 2 VEEG 1	Pt 3	Pt 4	Pt 5	Pt 6	Pt 7	Pt 8 VEEG 1	Pt 8 VEEG 2	Pt 9 VEEG 1	Pt 9 VEEG 2	Pt 9 VEEG 3	Pt 10 VEEG 1	Pt 10 VEEG 2	Pt 11 VEEG 1	Pt 11 VEEG 2	Pt 11 VEEG 3
Single-camera	nv	1 C 1 T + C + Y	1 v 1: 32s delay for Su, ED nv 1: ED nv	Jaw jerks: nv	nv	nv	nv	nv	nv	C + B + P: v	v	3 v	nv	Su & C: nv Myo: v	nv	1 C	nv	nv
Multi-camera	5 C1 T	2 T 1 C 1 C + T 1 T + C + Y	3 C1 with ED + Su	1 C1 jaw and 4 limbs jerks	3 C	1 eyelid + obicularis oris CI	7 Ny + eye rolling	4 C	3 Ny + ED + C 2 ED + C	3 EM 1 C (+ B + P)	8 C + T 1 C + T + B 1 C + H	5 C + T	1 C + T	4 Su 1 myo + Su 1 C	2 C 1 Su	4 Su 1 C	1 Su 1 C	2 C
EEG correlates	No	No	Unilateral SW, PSW	No	No	Unilateral delta	No	Temporal, anterior or occipital delta-theta	F-T delta-alpha + S-slowW	No	No	No	No	Yes (all Su and myo + Su) C Delta and theta- alpha	No	No	No	No
Other NS in the same VEEG	3 EI	No	No	No	5 EI 1 CI	No	No	NSE EI + 1 B + P	NSE EI	No	1 tonic + myo + C	No	No	NSE EI	No	No	No	No
EEG correlates	F delta (1), voltage attenuation + shw (2)	-	-	-	F-CT shw, S	-	-	Multifocal delta-theta	F-T delta-alpha + S-slowW	-	GT beta- alpha and S	-	-	Central Delta and theta- alpha	-	-	-	-
Detected events (single camera/ multicamera)	0/6	2/5	3/3	1/1 (partial)	0/3	0/1	0/7	0/4	0/5	1/4	10/10	3/5	0/1	1/6	0/3	1/5	0/2	0/2

Abbreviations: B, boxing; C, chewing automatisms; CI, clonic; CT, centro-temporal, ED, eye deviation; EEG, electroencephalogram; EI, electrographic-only; F, frontal; F-CT, fronto-centro-temporal; F-T, fronto-temporal; H, hiccup; myo, myoclonic; NS, neonatal seizures; NSE, neonatal status epilepticus; nv, not visible; Ny, nystagmus; P, pedalling; PSW, polyspike-and-waves; S, spikes; shw, sharp waves; SW, spike-and-waves; S-slow-W, spike-and-slow-wave; T, tongue automatisms; v, visible; Y, yawning automatisms.

what episodes actually represent seizures, with clear therapeutic implications. Furthermore, an important practical strength is that this aim can be achieved with very low additional costs, as we use a modified webcam to capture facial movements.

In addition, our method refines diagnostic accuracy in the case of neonatal seizures, by enabling clear attribution of a clinical correlation of “subtle” subtype to neonatal seizures which would otherwise be categorized as electrographic only. As an example, in our sample this would have occurred in four patients (5, 7, 8, and 10 in ▶Table 2). Therefore, our results seem to suggest that the relatively high occurrence of electrographic-only seizures reported in newborns might be partially related to the monitoring methods not allowing recognition of subtle clinical manifestations accompanying electrographic discharges. Although the existence of prognostic implications of the distinction between electroclinical and electrographic-only events is still a matter of debate, it is possible that, at least in a subset of patients, these differences point toward eloquent versus silent cortical areas.⁹ The availability of a bulk of detailed clinical information might provide the basis for a deeper understanding of the pathophysiology of neonatal seizures.

Finally, at a research level, the proposed method can allow a better delineation of clinical semiology of neonatal seizures, which might be especially relevant in the current debate on neonatal seizure classification.¹⁰ Furthermore, detailed documentation of even subtle or very focal motor events can be very useful when retrospectively evaluating polygraphic vEEG recordings for research purposes, because it might allow observation and description of phenomena which might have been overlooked in clinical practice, thus reducing the common issue of incomplete data collection in retrospective studies. Finally, detailed documentation and data storage of good resolution videos, recording even very subtle abnormal movements, is essential for further implementation of automated detection systems for neonatal seizures and paroxysmal abnormal movements based on video-processing algorithms.¹¹

In addition, these results could be obtained with low-cost technology, such as the webcams currently in use, with a cost (per camera) of approximately €20.

Conclusions

In summary, from our preliminary and descriptive data we conclude that using additional cameras, with one of which pointing toward the newborn’s face, can significantly

increase the quality of diagnostic monitoring of high-risk newborns and assist clinical research in neonatal neurology.

Conflict of Interests

The authors declare no potential conflict of interest with respect to the research, authorship, and/or publication of this article.

Funding

The authors declare no funding was secured for the completion of this study.

Ethical Approval

Local ethics committee approval was obtained.

References

- 1 Shellhaas RA. Continuous long-term electroencephalography: the gold standard for neonatal seizure diagnosis. *Semin Fetal Neonatal Med* 2015;20(3):149–153
- 2 Hahn JS, Sanger T. Neonatal movement disorders. *Neoreviews* 2004;5:e321–e326
- 3 Pisani F, Cerminara C, Fusco C, Sisti L. Neonatal status epilepticus vs recurrent neonatal seizures: clinical findings and outcome. *Neurology* 2007;69(23):2177–2185
- 4 Pisani F, Sisti L, Seri S. A scoring system for early prognostic assessment after neonatal seizures. *Pediatrics* 2009;124(4):e580–e587
- 5 Orivoli S, Facini C, Pisani F. Paroxysmal nonepileptic motor phenomena in newborn. *Brain Dev* 2015;37(9):833–839
- 6 Clancy RR, Legido A. The exact ictal and interictal duration of electroencephalographic neonatal seizures. *Epilepsia* 1987;28(5):537–541
- 7 Chang T, Tsuchida TN. Conventional (continuous) EEG monitoring in the NICU. *Curr Pediatr Rev* 2014;10(1):2–10
- 8 Malone A, Ryan CA, Fitzgerald A, Burgoyne L, Connolly S, Boylan GB. Interobserver agreement in neonatal seizure identification. *Epilepsia* 2009;50(9):2097–2101
- 9 Boylan GB, Stevenson NJ, Vanhatalo S. Monitoring neonatal seizures. *Semin Fetal Neonatal Med* 2013;18(4):202–208
- 10 Berg AT, Berkovic SF, Brodie MJ, et al. Revised terminology and concepts for organization of seizures and epilepsies: report of the ILAE Commission on Classification and Terminology, 2005–2009. *Epilepsia* 2010;51(4):676–685
- 11 Pisani F, Spagnoli C, Pavlidis E, et al. Real-time automated detection of clonic seizures in newborns. *Clin Neurophysiol* 2014;125(8):1533–1540